


available at www.sciencedirect.comjournal homepage: www.elsevier.com/locate/burns

Effects of silicone gel on burn scars

Mahnoush Momeni^a, Farhad Hafezi^{b,*}, Hossein Rahbar¹, Hamid Karimi^c

^a Motahary Burn and Reconstructive Centre, Iran University of Medical Sciences, Tehran, Iran

^b Department of Plastic Surgery, ST Fatima Hospital, Iran University of Medical Sciences, 15 Esmaeeli St, Keyhan Avenue, Zaferanieh, Tehran 1986884813, Iran

^c Department of Plastic Surgery, Motahary Burn and Reconstructive Centre, Iran University of Medical Sciences, Tehran, Iran

ARTICLE INFO

Article history:

Accepted 25 April 2008

Keywords:

Silicone gel

Hypertrophic scar

Burn

ABSTRACT

Aim: To study the efficacy of silicone gel applied to hypertrophic burn scars, in reducing scar interference with normal function and improving cosmesis.

Methods: A randomised, double-blind, placebo-controlled trial involving 38 people with hypertrophic burn scars. Each scar was divided into two segments; silicone gel sheet was applied randomly to one of the two and placebo to the other. Participants were seen again after 1 and 4 months. Their data and wound characteristics were collected using the Vancouver scar scale.

Results: The median age of participants was 22 years (1.5–60 years) and 16 were male; 4 did not attend follow-up and were excluded from the study. There were no significant differences in baseline characteristics. Although after 1 month all scar scale measures were lower in treated areas, only the vascularity scale was significantly different between the two areas. After 4 months, all scale measures were significantly lower in the silicone gel group than in the control group, except for the pain score.

Conclusion: Silicone gel is an effective treatment for hypertrophic burn scars.

© 2008 Elsevier Ltd and ISBI. All rights reserved.

1. Introduction

Wounds heal through scar formation, a complex natural process that consists of collagen deposition and re-epithelialisation, restoring the anatomical and structural integrity of the injured skin. Hypertrophic scars occur as a result of an exaggerated response of the skin following injury. In addition to raising cosmetic concerns, hypertrophic scars may be painful or pruritic and may restrict range of motion [1].

Scoring the degree of a thermal injury involves the age of the victim and the depth, extent and site of the burn. Burn scar management aims to prevent scars from interfering with function and to make them cosmetically acceptable. This goal should be achieved as comfortably, quickly and inexpensively

as possible [2]. In recent studies, application of silicone gel sheets has been advanced as one of various efficient non-operative burn scar therapies based on scientific evidence [3].

Numerous mechanisms have been suggested to explain the efficacy of the silicone gel, including hydration, pressure, temperature, oxygen transmission and silicone absorption. However, the exact mechanism of action remains unknown. Silicone gels have been used by Perkins et al. in Australia for treatment of burns since 1982. They showed significant improvement in burn scar maturation [2]; the silicone gel alone (without compression) made scars more flexible and smooth. However, no explanation was proposed. In a study by Ahn et al., silicone gel was found efficacious in both prevention and treatment of hypertrophic scars [4]. In view

* Corresponding author. Tel.: +98 21 2225 0623; fax: +98 21 2227 3233.

E-mail address: info@drhafezi.com (F. Hafezi).

¹ No current affiliation.

0305-4179/\$34.00 © 2008 Elsevier Ltd and ISBI. All rights reserved.

doi:10.1016/j.burns.2008.04.011

of the evident lack of controlled studies of silicone gel efficiency and the high incidence of symptomatic hypertrophic scars in our practice, we conducted a randomised, double-blind, placebo-controlled trial to evaluate silicone gel treatment of burn-induced hypertrophic scarring.

2. Materials and methods

From November 2005 to November 2006, 38 people with no history of keloid formation and with a healed, fully epithelialised, hypertrophic, homogenous burn scar of at least 5 cm × 5 cm in area, were selected. The exclusion criteria were wound infection, open wound or sensitivity to silicone gel. The study was approved by our university's ethics council, all participants having filled out informed consent forms.

The silicone gel (Cica-Care, Smith and Nephew, Hull, UK) comprised semi-occlusive self-adhesive sheeting made from medical-grade silicone reinforced with silicone membrane backing. The placebo comprised self-adhesive propylene glycol and hydroxyethyl cellulose sheeting. Both silicone and placebo sheets were applied for 4 h/day with a 4-h daily increment to 24 h/day. Overlay taping was used when needed.

A random number table was used for the coding and randomisation of the gel and placebo samples. Silicone gels were applied to one segment of a single burn scar, such as the upper or lower part of the left forearm, and the other segment was covered with placebo (Figs. 1 and 2). Treatment was started 2–4 months after injury. Participants were followed up at 1 and 4 months after starting treatment. The gel and placebo sheets were removed for each examination, and each participant was sent to another plastic surgeon for the wound to be evaluated blindly. A digital camera recorded the serial changes in the wounds, taking front and profile views during each follow-up visit. An information protocol form was used to collect the participant's data and wound characteristics (pigmentation, vascularity, pliability, pain and itchiness) according to a modified version of the Vancouver scar scale, excluding height [5].

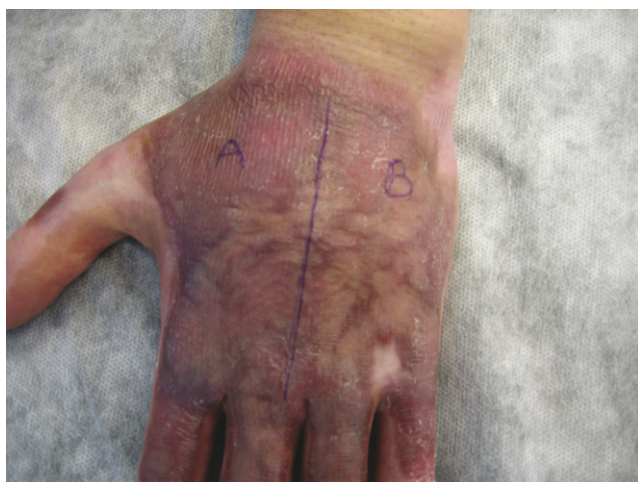

Fig. 1 – Burn scars randomly divided into two areas for treatment or placebo.

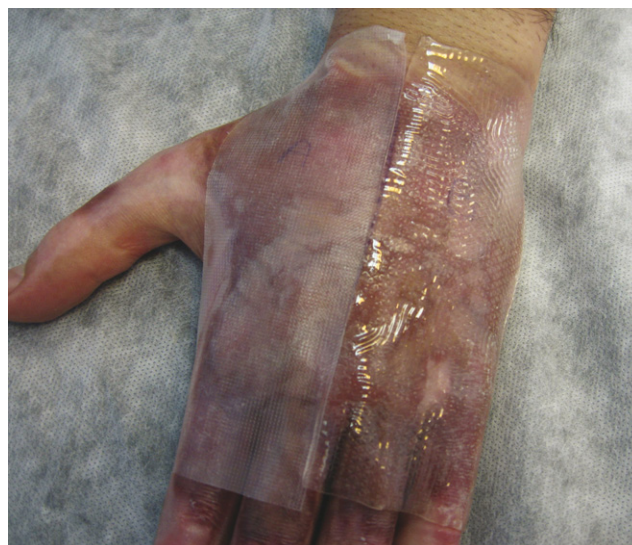

Fig. 2 – Application of silicone sheet and placebo.

Previous reports recommended using the silicone sheet for 12–24 h daily, which requires washing the scar and reapplying the silicone sheet. Side effects include pruritis, rash, maceration and foul smells; if side effects develop, therapy is immediately discontinued [6,7].

SPSS software version 14 was used for analysis of the results. Significant differences in various scar parameters between the two groups were detected by the Wilcoxon signed ranks test. A *p*-value <0.05 was considered significant.

3. Results

Four participants were lost to follow-up (two because of distance and two because of failure respond). The median age of the remaining 34 participants was 22 years (1.5–60 years); 16 were male and 18 were female. The burns were distributed as follows: 4 on the hand, 8 on the upper arm, 2 on the forearm, 7 on the thigh, 1 on the lower leg, 9 on the face and 3 on the trunk.

The results of treatment are shown in Table 1, scored according to the modified Vancouver scale. There were no significant differences in baseline characteristics. At the first visit (1 month after starting therapy), all scar scores were lower in the silicone gel area than in the control area, but only the vascularity scale was significantly different between the two. At the second follow-up (4 months after starting therapy), all scores except pain were significantly lower in the silicone gel group compared with the control group (Fig. 3). No side effects of the silicone gel were noted in any case.

4. Discussion

There are many factors which may contribute to scar overgrowth, including ethnicity, other genetic influences,

Table 1 – Vancouver scar scale scores at different time points: mean values ± standard error of mean

Scar characteristic	Intervention	Baseline	First follow-up	Second follow-up
Pigmentation	Silicone gel	1.24 ± 0.14	0.79 ± 0.13	0.29 ± 0.08 ^a
	Placebo	1.21 ± 0.11	0.88 ± 0.09	0.59 ± 0.09
Vascularity	Silicone gel	2.18 ± 0.15	1.59 ± 0.16 ^a	0.97 ± 0.18 ^a
	Placebo	2.12 ± 0.18	1.79 ± 0.20	1.50 ± 0.21
Pliability	Silicone gel	3.15 ± 0.19	2.0 ± 0.22	0.97 ± 0.13 ^a
	Placebo	2.97 ± 0.19	2.32 ± 0.21	1.74 ± 0.21
Pain	Silicone gel	1.24 ± 0.15	1.0 ± 0.15	0.76 ± 0.14
	Placebo	1.29 ± 0.13	1.15 ± 0.14	0.88 ± 0.14
Itchiness	Silicone gel	1.56 ± 0.11	0.94 ± 0.15	0.41 ± 0.10 ^a
	Placebo	1.50 ± 0.12	1.24 ± 0.15	0.97 ± 0.16

^a The silicone gel group’s score was significantly lower than the placebo group’s score; Wilcoxon signed ranks test was used ($p < 0.05$).

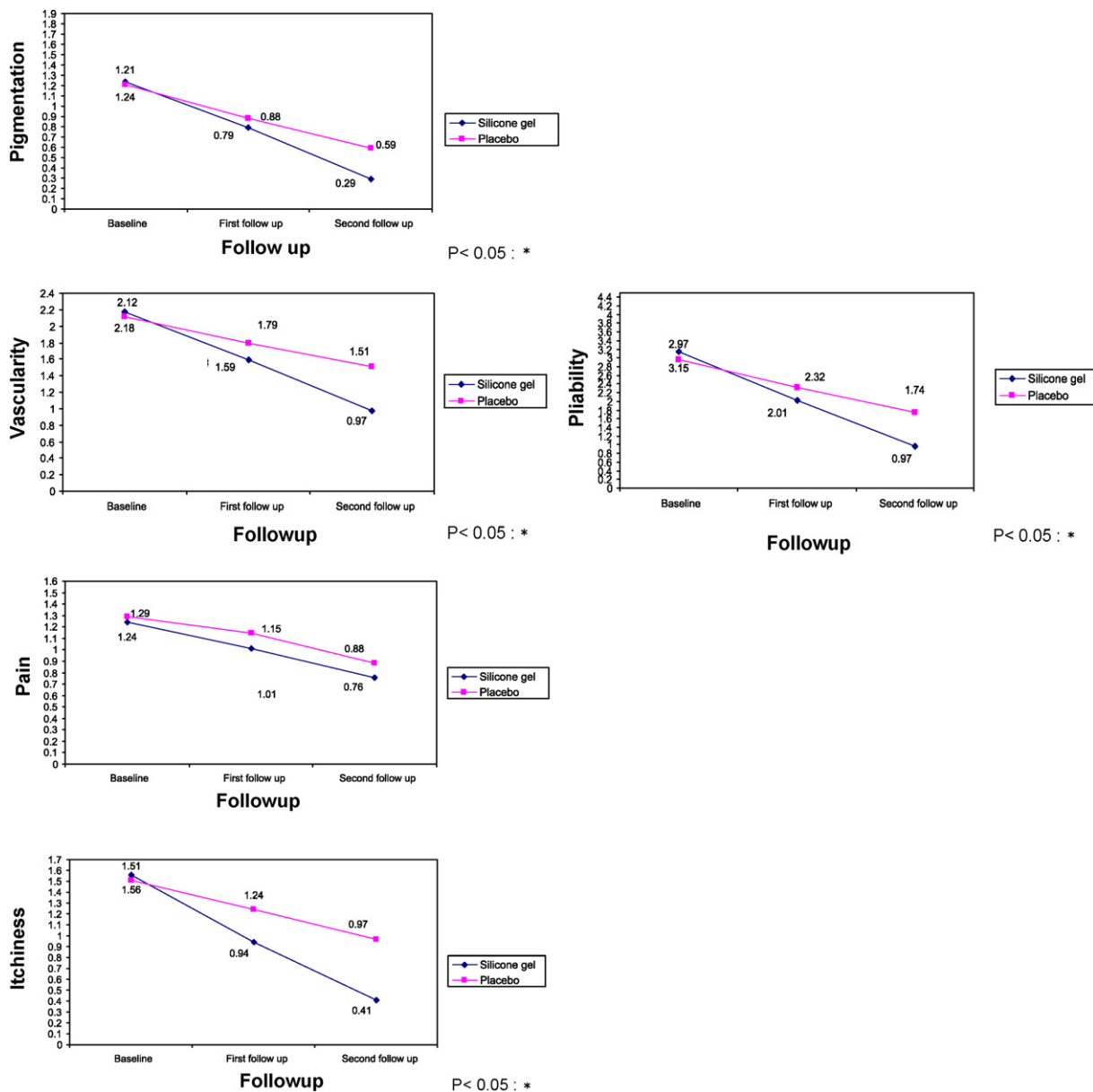


Fig. 3 – Vancouver scar scales applied to our cases; $p < 0.05$.

anatomical region affected, wound depth, injury type, presence of infection and prolonged immune responses. Evidently for some predisposed individuals, healing processes may produce excessive wound matrix which causes itching and pain. Excessive scar formation is simply the end result of this process [8] and can lead to serious functional and cosmetic problems.

Perkins et al. developed the earliest known silicone gel sheet for use at 6–8 weeks after the initial injury, when the scars started to develop [2]. All scars tend to worsen over the first 3–4 months as collagen deposition and contracture take place in the setting of increased active anabolism. Thereafter, anabolism slows and collagenase tends to produce enough scar breakdown for hypertrophic scars slowly to begin to reduce in size, soften and become less erythematous (this is referred to as scar maturation). Because of this, in all studies, placebo treatment shows a decrease in scar severity over the first few months, but less than in cases treated with silicone gel. There are many controversial studies on the efficacy of silicone gel sheets for therapy of hypertrophic scars [1,4,9–11], but very little of the available evidence is based on well-controlled trials [13]; most of these investigations examine diverse types of scars, with enigmatic conclusions.

Ahn et al. demonstrated the effectiveness of silicone in the treatment of chronic scars to a greater extent [4], but the mechanism of action and physiological effects of silicone gel remain unclear [13]. There is some evidence that the treatment affects the stratum corneum and, by reducing evaporation, restores better homeostasis in the tissue [14,15]. In keloid and hypertrophic scarring, the stratum corneum allows more evaporation of water from the underlying tissue than occurs in normal skin [16]. Silicone sheets may prevent this, keeping the stratum corneum in optimal hydration [17] and protecting the skin from environmental hazards, both of which can reduce abnormal scarring [18]. The gel may also affect the stratum corneum by inhibiting mast cell activity, diminishing oedema, vasodilatation and excessive extracellular matrix formation [12], but the simple changes in temperature, pressure, oxygen tension and hydration produced by wound coverage probably constitute the main mechanism of action [12,19,20]. Another hypothesis is that the effect of static electricity on silicone may influence the alignment of collagen deposition [21].

The main finding of this paper was the reduction of hypertrophic scar scores among our participants after silicone gel application. Pigmentation, vascularity, pliability and itching were reduced significantly in comparison with controls (Fig. 3). Our results are further confirmed by a recent paper from Chan et al. [12], studying scarring of sternal wounds in population of different ethnicity.

5. Conclusion

Our results suggest that application of silicone gel is effective in reducing hypertrophic burn scars. Without an animal model, a well-controlled trial to study hypertrophic scar

pathophysiology and treatment is difficult. However, we tried to decrease the variables affecting the scar tissue by including only burn scars and placing treatment and control areas on the same anatomical region of the same participant. The majority of evidence suggests that silicone does have some beneficial effect on scarring and, because this is a non-invasive method and easy to use, more conclusive controlled testing in clinical trials is warranted to gain uniform acceptance.

REFERENCES

- [1] Alster TS, West TB. Treatment of scars: a review. *Ann Plast Surg* 1997;39:418.
- [2] Perkins K, Davy RB, Wallis KA. Silicone gel: a new treatment for burn scars and contractures. *Burns* 1982;9:201–4.
- [3] Mustoe TA, Cooter RD, Gold MH, Hobbs FD, Ramelet AA, Shakespeare PG, et al. International clinical recommendations on scar management. *Plast Reconstr Surg* 2002;110:560–71.
- [4] Ahn ST, Monafu WW, Mustoe TA. Topical silicone gel for the prevention and treatment of hypertrophic scar. *Arch Surg* 1991;126:499–504.
- [5] Nedelec B, Shankowsky HA, Tredget EE. Rating the resolving hypertrophic scar: comparison of Vancouver scar scale and scar volume. *J Burn Care Rehabil* 2000;21:205–12.
- [6] Nessen FB, Spauwen PH, Schalkwijk J, Kon M. On the nature of hypertrophic scars and keloid: a review. *Plast Reconstr Surg* 1999;104:1435.
- [7] Cruz-Korchin NI. Effectiveness of silicone sheets in the prevention of hypertrophic breast scars. *Ann Plast Surg* 1996;37:345.
- [8] Nikonen MMPitkanen JM, Al-Qattan MM. Problems associated with the use of silicone gel sheeting for hypertrophic scars in the hot climate of Saudi Arabia. *Burns* 2001;27:498.
- [9] Sproat JE, Dalcin A, Weitauer N, Roberts RS. Hypertrophic sternal scars: silicone gel sheet versus kenalog injection treatment. *Plast Reconstr Surg* 1992;90:988–92.
- [10] O'Sullivan ST, Oshaughnessy M, O'Connor TP. Etiology and management of hypertrophic scars and keloid. *Ann R Coll Surg Engl* 1996;78:168–75.
- [11] Quinn KJ, Evans JH, Courtney JM, Gaylor JD, Reid WH. Non-pressure treatment of hypertrophic scars. *Burns* 1985;12:102.
- [12] Chan KY, Lau CL, Adeeb SM, Somasundaram S, Nasir-Zahari M. A randomized, placebo controlled, double blind, prospective clinical trial of silicone gel in prevention of hypertrophic scar development in median sternotomy wound. *Plast Reconstr Surg* 2005;116:1013–20.
- [13] Glenn Lyle W. The Plastic Surgery Educational Foundation DATA Committee. Silicone gel sheeting. *Plast Reconstr Surg* 2001;107:272–5.
- [14] Musgrave MA, Umraw N, Gomez M, Cartotto RC. The effect of silicone gel sheets on perfusion of hypertrophic burn scars. *J Burn Care Rehabil* 2002;23:208–14.
- [15] Gilman TH. Silicone sheet for treatment and prevention of hypertrophic scar: a new proposal for the mechanism of efficacy. *Wound Repair Regen* 2003;11:235–6.
- [16] Suetake T, Sasai S, Zhen YX, Ohi T, Tagami H. Functional analyses of the stratum corneum in scars: sequential studies after injury and comparison among keloids, hypertrophic scars, and atrophic scars. *Arch Dermatol* 1996;132:1453–8.

- [17] Suetake T, Sasai S, Zhen YX, Ohi T, Tagami H. Effect of silicone gel sheet on the stratum corneum hydration. *Br J Plast Surg* 2000;53:503-7.
- [18] Mustoe T. Evolution of silicone therapy and mechanism of action in scar management. *Aesth Plast Surg* 2008;32:82-92.
- [19] Davey RB, Wallis KA, Bowering K. Adhesive contact media: our update on graft fixation and burn scar management. *Burns* 1991;17:313-9.
- [20] Chang CC, Kuo YF, Chiu HC, Lee JL, Wong TW, Jee SH. Hydration modulates the effects of keratinocytes on fibroblasts. *J Surg Res* 1995;59:705.
- [21] Hirshowitz B, Lindenbaum E, Har-shai Y, Feitelberg L, Tendler M, Katz D. Static electric field induction by a silicone cushion for the treatment of hypertrophic and keloid scars. *Plast Reconstr Surg* 1998;101:1173-83.